
Principles of the Oxford Operation

This chapter is intended to be read in parallel with the description of the operative technique (Chapter 7). That chapter is concerned with 'how' to do the operation; this chapter provides the rationale—'why' the various steps of the procedure are necessary. It may help also to watch the videos of the operation which can be found at www.oxfordpartialknee.com.

Although the surgeon operates exclusively on the bones, carefully avoiding any interference with the ligaments, the operation is essentially about 'soft tissue balance'. The aim is to implant the prosthetic surfaces so that the ligaments are at their resting tensions throughout the range of passive movement. This should restore both normal alignment, normal mobility and normal stability.

In what follows, we will often refer to the 'gap' between the medial femoral and tibial condyles, meaning the space between them created by distraction of their surfaces. With the muscles relaxed, the width of this gap can be used as a measure of the lengths of the ligaments spanning it.

The ligaments

The normal intact knee

In full extension, most of the fibres of the ligaments of the normal knee and the posterior capsule are just tight (i.e. at their resting unstretched lengths), and neither the medial nor the lateral joint surfaces can be separated without applying force to stretch the ligaments. With the knee flexed (beyond about 20°) all the fibres of the posterior capsule and the LCL slacken, and distraction of the articular surfaces produces a gap in either compartment. These 'physiological' gaps are limited by the compliance of the other three ligaments that span the joint (the MCL and the cruciates), some of whose fibres maintain their resting tension and remain isometric throughout the range of passive flexion (see Chapter 3 and Appendix).

The effect of increasing flexion on the width of these gaps is different in the two compartments.

In the **lateral compartment**, the gap produced by distraction increases with increasing flexion to about 7 mm at 90° (mean 6.7 ± 1.9 mm) (Fig. 6.1(b))¹.

In the **medial compartment**, the width of the gap does not alter significantly throughout the range of passive flexion, measuring about 2 mm at 90° (mean 2.1 mm ± 1.1 mm) (Fig. 6.1(c)).

Since the LCL and the posterior capsule are demonstrably slack in the flexed knee, the constant width of the medial gap at all angles of flexion (except full extension) implies that the MCL and the cruciates exert a net isometric effect on that compartment throughout that range of movement. After medial unicompartmental replacement, both the stability of the knee and the entrapment of the free bearing depend upon reproducing this isometric mechanism. (The difference between the compliance of the two compartments in flexion explains why bearing dislocation is a problem laterally.)

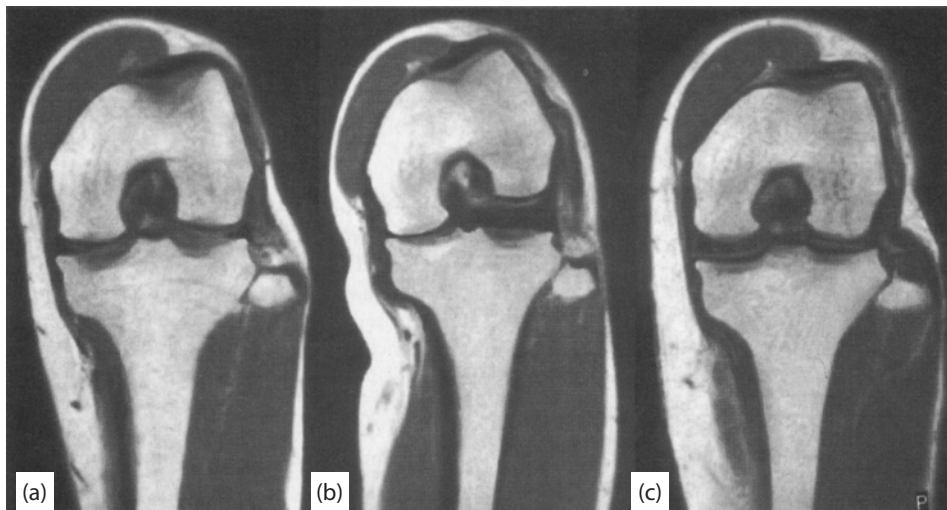

Figure 6.1 Representative MR scans of the left knee in (a) a neutral position, (b) under passive varus stress, and (c) under passive valgus stress. (Reproduced with permission and copyright © of the British Editorial Society of Bone and Joint Surgery [Tokuhara Y, Kadoya Y, Nakagawa S, Kobayashi S and Takaoka K. The flexion gap in normal knees. An MRI study. *J Bone Joint Surg [Br]* 2004; **86-B**: 1133–6].)

The knee with anteromedial osteoarthritis

In anteromedial OA, the MCL and the cruciate ligaments are intact and have the same mechanical effects as in the normal joint. However, the posterior capsule tends to be shortened and there is an associated fixed flexion deformity. The effect of this is to close down the medial compartment gap *before full extension is reached* (Figs. 6.2(a) and 6.2(b)). For this reason, we assess the gap with the knee flexed at 20° to ensure that the posterior capsule is slack (Fig. 6.2(c)). (In anteromedial OA with an intact ACL, the flexion deformity tends to be less than 15°, so 20° flexion should always achieve this.)

In all positions of flexion greater than 20°, the medial condyles can be distracted the same distance as in the normal knee because the gap is limited by the normal MCL and cruciates. Therefore, distraction in flexion above 20° (Fig. 6.2(c)) restores normal alignment of the leg (Fig. 6.2(d)). The medial gap appears wider than normal only because cartilage and bone have been lost from the joint surfaces.

Balancing the ligaments in TKA and OUKA

In TKA, the term 'ligament balancing' usually implies elongation of the MCL by medial release to match the length of the LCL so that, at 90° flexion, the medial and lateral gaps are equal (the flexion gap is quadrilateral, Fig. 4.14(e)). As Figures 1.10 and 6.1(b) demonstrate, this is not the physiological state.

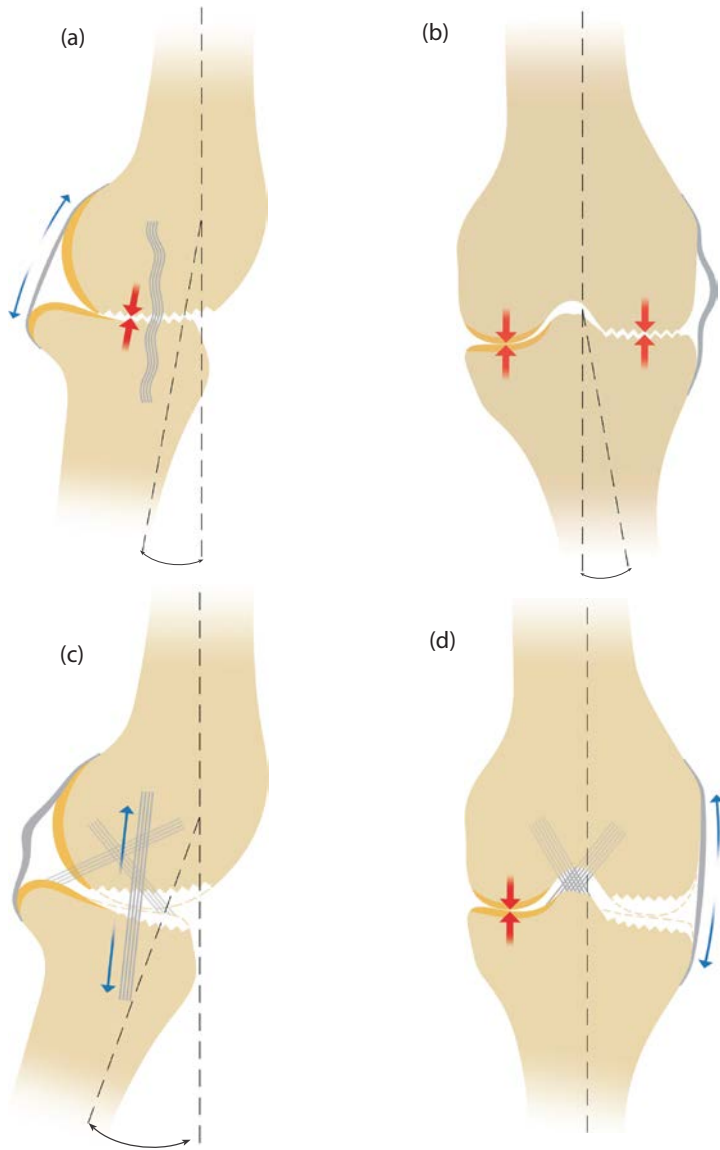


Figure 6.2 (a) With the knee extended, as far as possible, the shortened posterior capsule closes down the medial gap before full extension is reached, causing a flexion deformity, and (b) a varus deformity that is not correctable although the MCL is slack (c). At 20° flexion, however, the posterior capsule is slack and (d) an applied valgus force can distract the damaged medial articular surfaces. Because the MCL is of normal length, this corrects the varus deformity.

In OUKA, medial release should never be undertaken. The MCL is of normal length in anteromedial OA; mobility and stability of the joint, alignment of the leg, and entrapment of the bearing all depend upon its integrity. *Balancing the ligaments means adjusting the position of the femoral component relative to the femur (by removing bone) so that the medial distraction gap is the same in flexion and extension.*

In other words the 'flexion gap' and 'extension gap' should be equal. As explained above, the extension gap is measured in 20° flexion because the posterior capsule is slack. The flexion gap is measured at 90° to this, at 110° knee flexion. The instrumentation is designed to adjust the extension gap without changing the flexion gap. The flexion gap is established first, then the extension gap is adjusted to match it by milling bone from the inferior femoral condyle.

Because the lateral collateral ligament plays no part in the balancing of ligaments in OUKA, it is not represented on any of the explanatory diagrams.

The joint level

The prosthetic joint level

The prosthetic joint level is shown in the construct in Figure 6.3. It is at the interface between the femoral component and the polyethylene bearing, the level at which flexion–extension occurs. The operation aims to remove enough bone from the femoral and tibial condyles to create a flexion gap that the constructed implant will just fill. The thickness of the posterior facet of the femoral component varies with its radius from 5.50 mm (extra small) to 7.45 mm (extra large). The thickness of the tibial component is 3 mm which is constant throughout the range of sizes. The thinnest bearing usually considered safe to use (3 mm) has 3.5 mm of polyethelene at its thinnest point. We do however recommend a 4 mm bearing for all but small and extra small femoral components.

In this respect, the thickness of bone removed from the tibia is not critical. If more is removed than the minimum required, the widths of the flexion and extension gaps are increased equally, and their 'balance' does not alter. A thicker bearing will be needed to restore stability, but this will affect neither the joint level nor, therefore, the kinematics of the replaced compartment (Fig. 6.3(c)).

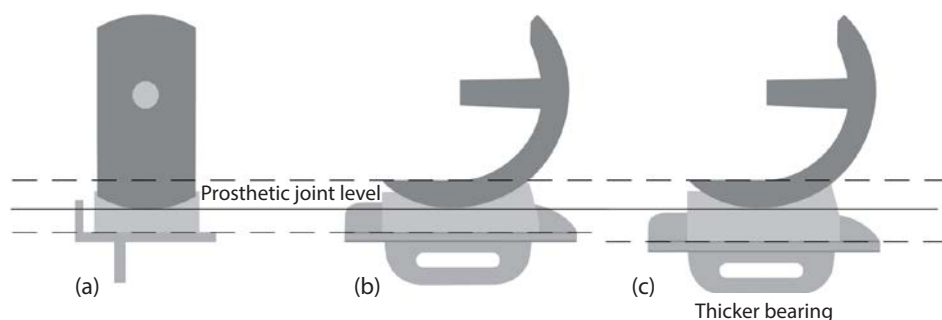


Figure 6.3 The prosthetic joint level, the continuous solid line.